



## Original Contribution

# Bedside lung ultrasound in the assessment of alveolar-interstitial syndrome

Giovanni Volpicelli<sup>a,\*</sup>, Alessandro Mussa<sup>a</sup>, Giorgio Garofalo<sup>b</sup>, Luciano Cardinale<sup>b</sup>,  
Giovanna Casoli<sup>a</sup>, Fabio Perotto<sup>b</sup>, Cesare Fava<sup>b</sup>, Mauro Frascisco<sup>a</sup>

<sup>a</sup>Department of Emergency Medicine, S. Luigi Hospital, Orbassano (TO) 10043, Italy

<sup>b</sup>Institute of Radiology, S. Luigi Hospital, Orbassano (TO) 10043, Italy

Received 23 December 2005; revised 2 February 2006; accepted 17 February 2006

## Abstract

**Objectives:** To assess the potential of bedside lung ultrasound to diagnose the radiologic alveolar-interstitial syndrome (AIS) in patients admitted to an emergency medicine unit and to estimate the occurrence of ultrasound pattern of diffuse and multiple comet tail artifacts in diseases involving lung interstitium.

**Methods:** The ultrasonic feature of multiple and diffuse comet tail artifacts B line was investigated in each of 300 consecutive patients within 48 hours after admission to our emergency medicine unit. Sonographic examination was performed at bedside in a supine position. Eight anterolateral ultrasound chest intercostal scans were obtained for each patient.

**Results:** The artifact showed a sensitivity of 85.7% and a specificity of 97.7% in recognition of radiologic AIS. Corresponding figures in the identification of a disease involving lung interstitium were 85.3% and 96.8%.

**Conclusion:** Comet tail artifact B line is a lung ultrasound sign reasonably accurate for diagnosing AIS at bedside.

© 2006 Elsevier Inc. All rights reserved.

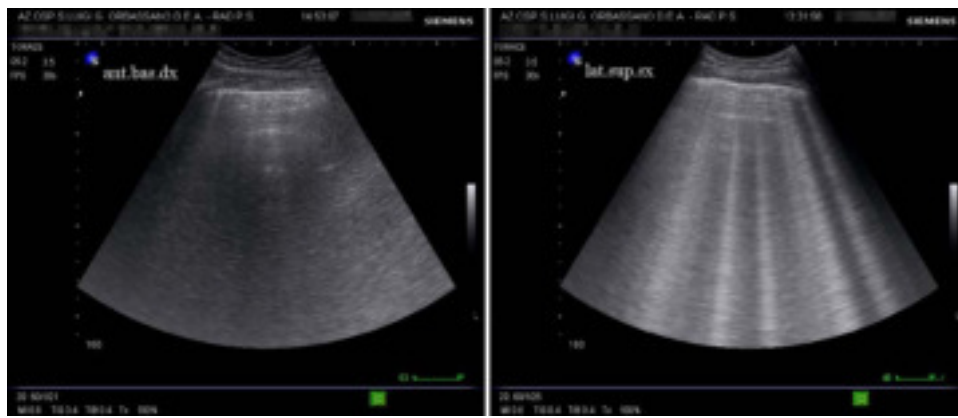
## 1. Introduction

The alveolar-interstitial syndrome (AIS) of the lung includes several heterogeneous conditions with diffuse involvement of the interstitium and impairment of the alveolocapillary exchange capacity, which leads to more or less severe respiratory failure. Such conditions are either chronic (eg, pulmonary fibrosis) or acute (eg, acute respiratory distress syndrome (ARDS), acute pulmonary

edema, interstitial pneumonia). Lung ultrasound is a noninvasive technique potentially useful in detecting AIS at bedside. Sonographic diagnosis of AIS relies on the detection of multiple and diffuse comet tail B lines at lung scans [1–3]. These are vertical artifacts fanning out from the lung-wall interface and spreading up to the edge of the screen (Fig. 1). They are due to thickened interlobular septa and extravascular lung water and have been found to be associated with bedside diagnosis of diffuse infiltrative lung diseases, pulmonary edema, and ARDS in critically ill patients [2]. Other authors found diffuse comet tail artifacts in patients with diffuse parenchymal lung disease [4,5]. Jambrik et al [6] showed the usefulness of the artifacts as a

\* Corresponding author. S.C.D.O. Medicina d'Urgenza, Ospedale San Luigi da Orbassano, Torino, Italy. Tel.: +39 11 9026603 9026827.

E-mail address: gio.volpicelli@tin.it (G. Volpicelli).



**Fig. 1** (Left panel) Normal ultrasound lung scan with horizontal hyperechogenic lines regularly spaced due to reverberation of the lung wall. Absence of vertical artifacts. (Right panel) Comet tail vertical artifacts fanning out from the lung-wall interface and spreading up to the edge of the screen (B line) from a patient with acute pulmonary edema.

nonradiologic sign of extravascular lung water. More recently, Agricola et al [7] showed that, in cardiac surgery patients without lung diseases, the number of comet tail images provides an estimate of extravascular lung water.

Detecting lung AIS is of great importance in the evaluation of dyspneic patients in the ED. Normally, diagnosis of AIS depends on pulmonary high resolution computerized scanning, but in the ED, we are usually dependent upon plain radiography. When chest x-ray is performed at bedside, it may be technically deficient. Nevertheless, it remains the only basis for taking therapeutic decisions. In the evaluation of dyspneic patients presented to the ED, plain film showed high specificity with low sensitivity in diagnosing congestive heart failure [8]. Lung ultrasound is easy to be implemented and potentially useful in detecting AIS at bedside. When performed by the attending emergency physicians, it is not time consuming and permits real-time assessment of dyspneic patients.

The present study aims at assessing the potential of bedside lung ultrasound to diagnose AIS in internal medicine inpatients and aims at estimating feasibility and interobserver agreement in the detection of B line artifacts.

## 2. Methods

The study was conducted at San Luigi community Hospital, Orbassano. It is a university hospital in the west side of Turin. The ED serves a primarily adult population with a volume of approximately 40,000 visits per year. The same emergency physician group attending the ED cover the 9 beds of the adult emergency medicine unit.

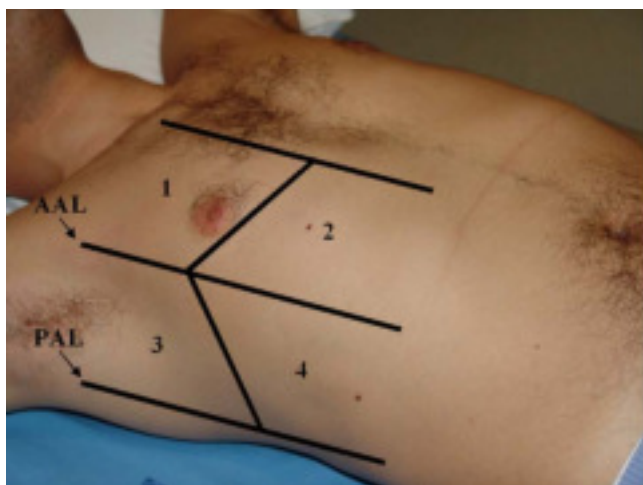
### 2.1. Patients population

During a 10-month period (from June 2004 to March 2005), 300 consecutive patients admitted to our emergency medicine unit were studied (186 men, 114 women, mean age  $68.4 \pm 15.2$  years [ $\pm$ SD]). Patients gave informed consent before entering the study. All underwent chest x-ray

before admission, and a lung ultrasound was performed within 48 hours during hospital stay. Five patients (1 with mesothelioma, 2 with fibrothorax, and 2 with lung cancer who had undergone extended pneumonectomy) were excluded because of noninterpretable ultrasound and/or chest radiograph because of lack of lung-wall interface or bad quality plain film. Among the remaining 295 patients, 135 were with diagnosed conditions irrelevant to cardiopulmonary changes and 160 had a cardiac and/or pulmonary involvement. Out of the latter, for 75, the final clinical diagnosis was AIS. Clinical features observed in these AIS patients were congestive heart failure in 59 patients, pulmonary fibrosis in 6, interstitial pneumonia in 3, pulmonary tuberculosis miliaris in 3, multiple bilateral pneumonia in 3, and ARDS in 1. Among patients with cardiopulmonary diseases, 84 had a diagnosis other than diffuse AIS. They were 32 instances of isolated pneumonia, 12 of pulmonary cancer, 26 of exacerbation of chronic obstructive pulmonary disease (COPD), 6 of pulmonary thromboembolic disease, 3 of pleurisy, 2 of exacerbation of asthma, 5 of decompensated cor pulmonale in obstructive or restrictive lung disease, and 1 of idiopathic pulmonary hypertension. Three had more than one diagnosis. In all cases, confirmation of the diagnosis was based on medical history recorded at presentation, x-ray images, results of tests such as echocardiography or left ventriculography, pulmonary function examination, response to therapy during the hospital course, and follow-up at 1 month.

### 2.2. Chest radiograph

Each patient underwent posterior-anterior chest radiograph using a commercially available radiograph machine and a standard technique. Critically ill patients were submitted to bedside x-ray with a portable unit. The film was read by an independent radiologist who was unaware of ultrasound and clinical findings. Diagnoses were grouped into 2 series, with and without radiological evidence of diffuse AIS (presence of diffuse and bilateral alveolar and/or interstitial opacities, either as confluent, septal, linear or



**Fig. 2** The areas of thoracic ultrasonography considered in the study. Areas 1 and 2: upper anterior and lower anterior; areas 3 and 4: upper lateral and basal lateral. Each area was the same on right and left side. AAL, anterior axillary line; PAL, posterior axillary line.

nodular, distension of pulmonary veins, redistribution to the apices, and interstitial edema). Seventy-seven patients had a radiologic evidence of AIS. Among the 218 patients without radiologic evidence of diffuse AIS, 63 had a radiologic diagnosis of localized and unique lung parenchymal or interstitial thickening.

### 2.3. Lung ultrasound

A GS 50 portable unit (Siemens, Germany), equipped with a convex 3.5-MHz transducer, was used. The investigator was unaware of the result of the chest radiogram and clinical data of the patient. Five specifically trained investigators (3 emergency physicians and 2 radiologists) performed the bedside lung ultrasound examinations. These consist bilateral scanning of the anterior and lateral chest wall and were performed with patients in supine or near-to-supine position. The correct scan was intercostal with the maximum extension of the visible pleural line. The chest wall was divided into 8 areas, and 1 scan for each area was obtained. The areas were 2 anterior and 2 lateral per side (Fig. 2). The anterior chest wall was delineated from the sternum to the anterior axillary line and was subdivided into upper and lower halves (approximately from clavicle to the second-third intercostal spaces and from the third space to diaphragm). The lateral zone was delineated from the anterior to the posterior axillary line and was subdivided into upper and basal halves. Each image was recorded on a CD-ROM. A random set of 24 examinations were performed twice by 2 independent observers among the 5 mentioned above to assess interobserver variability. Thus, the 295 patients produced a total of 2552 scans. The elementary image analyzed was the comet tail artifact fanning out from the lung-wall interface and spreading up to the edge of the screen, previously named B line [3]. The

pattern which was considered abnormal had all of the following 3 features: (1) multiple artifacts per scan (at least 3 artifacts), (2) diffuse positivity in more than one scan per side, and (3) bilateral positivity. Thus, a positive ultrasound test for AIS was defined as the presence of multiple, diffuse, and bilateral artifacts. Patients with positive and negative ultrasound were, respectively, 71 and 224. Lung ultrasound examinations were never longer than 3 minutes.

### 2.4. Thoracic computed tomography

In 18 cases, a thoracic computed tomography (CT) scan was recorded within 2 days on admission for clinical reasons not linked to our study protocol. They were 1 basal CT, 4 high-resolution CT, and 13 contrast-enhanced CT scans. CT examinations were performed from the apex to the diaphragm. Images were analyzed by an independent radiologist, who was unaware of results of other tests and clinical data. Attention was focused on the presence of diffuse signs of thickened interlobular septa, ground-glass areas, and multiple and diffuse parenchymal thickening.

## 3. Results

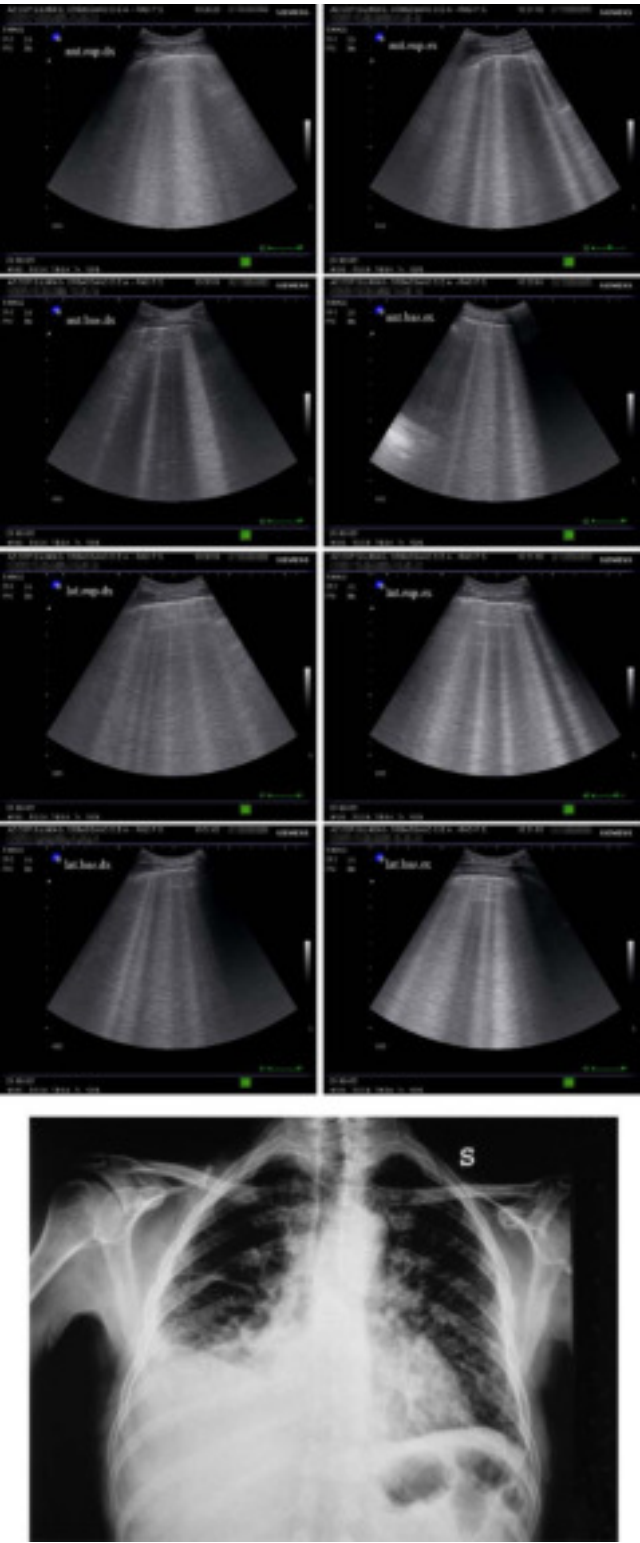
Among 300 cases studied, ultrasound and chest radiograph findings could be compared in 295. In only 5 patients could a scan not be compared with plain film. They had noninterpretable ultrasound (2 patients with pneumonectomy in lung cancer and 2 patients with fibrothorax, because of lack of lung-wall interface) or noninterpretable radiograph (1 patient with mesothelioma, because of technically deficient image). In the 24 randomly selected patients who performed double ultrasound examination, we obtained 183 concordant and 9 discordant scan diagnoses, with an interobserver variability on interpretation of the single scan of 4.9%.

### 3.1. Ultrasound versus chest x-ray

The association between the presence of the artifacts and radiologic findings was investigated (Table 1). When considering all ultrasounds with multiple and diffuse B lines (at least 2 positive scans on each side) as positive for

**Table 1** Agreement between sonographic pattern of AIS and radiologic findings

Findings at x-ray	Sonographic findings		Total
	>1 Positive scan per side	Negative ultrasound	
Diffuse AIS	66	11	77
Localized lung lesion and negative AIS	3	60	63
Negative chest x-ray	2	153	155
Total	71	224	295



**Fig. 3** Acute pulmonary edema. (Upper panel) Ultrasound pattern positive for AIS: comet tail artifacts are multiple (at least 3) in each scan and diffuse in all the 8 anterior and lateral scans (4 per side). (Lower panel) Corresponding chest x-ray showing signs of pulmonary hypertension and pleural effusion.

AIS, this sign had a sensitivity of 85.7% and a specificity of 97.7% for diagnosing radiologic AIS, with a positive predictive value of 93.0% and a negative predictive value of 95.1%. Among the 59 patients with congestive heart failure, 49 had a positive ultrasound, 55 had a positive radiograph, and 48 had a concordant positive chest x-ray and ultrasound (Fig. 3). Sixteen discordant cases were noted (11 false negative and 5 false positive). False-negative cases include 8 acute left heart failure, 2 exacerbation of COPD, and 1 pneumonia. False-positive cases include 1 rheumatoid arthritis, 2 right-sided pneumonia, 1 congestive heart failure, and 1 fever in aplastic anemia.

**3.2. Ultrasound versus clinical outcome**

Using the same criteria, the agreement between the presence of the artifacts and the clinical diagnosis at discharge was also estimated (Table 2). Lung ultrasound with diffuse B lines had a sensitivity of 85.3% and a specificity of 96.8% for diagnosing a disease with alveolar-interstitial involvement, with a positive predictive value of 90.1% and a negative predictive value of 95.1%. Eighteen discordant cases were noted. Eleven cases were false negative and 7 were false positive. False-negative cases include 10 acute left cardiac failure (7 with positive and 3 with negative chest x-ray) and 1 multiple and diffuse bilateral pneumonia. False positives include 4 right pneumonia (3 basal, 1 apical), 1 lung cancer, 1 rheumatoid arthritis, and 1 fever in aplastic anemia.

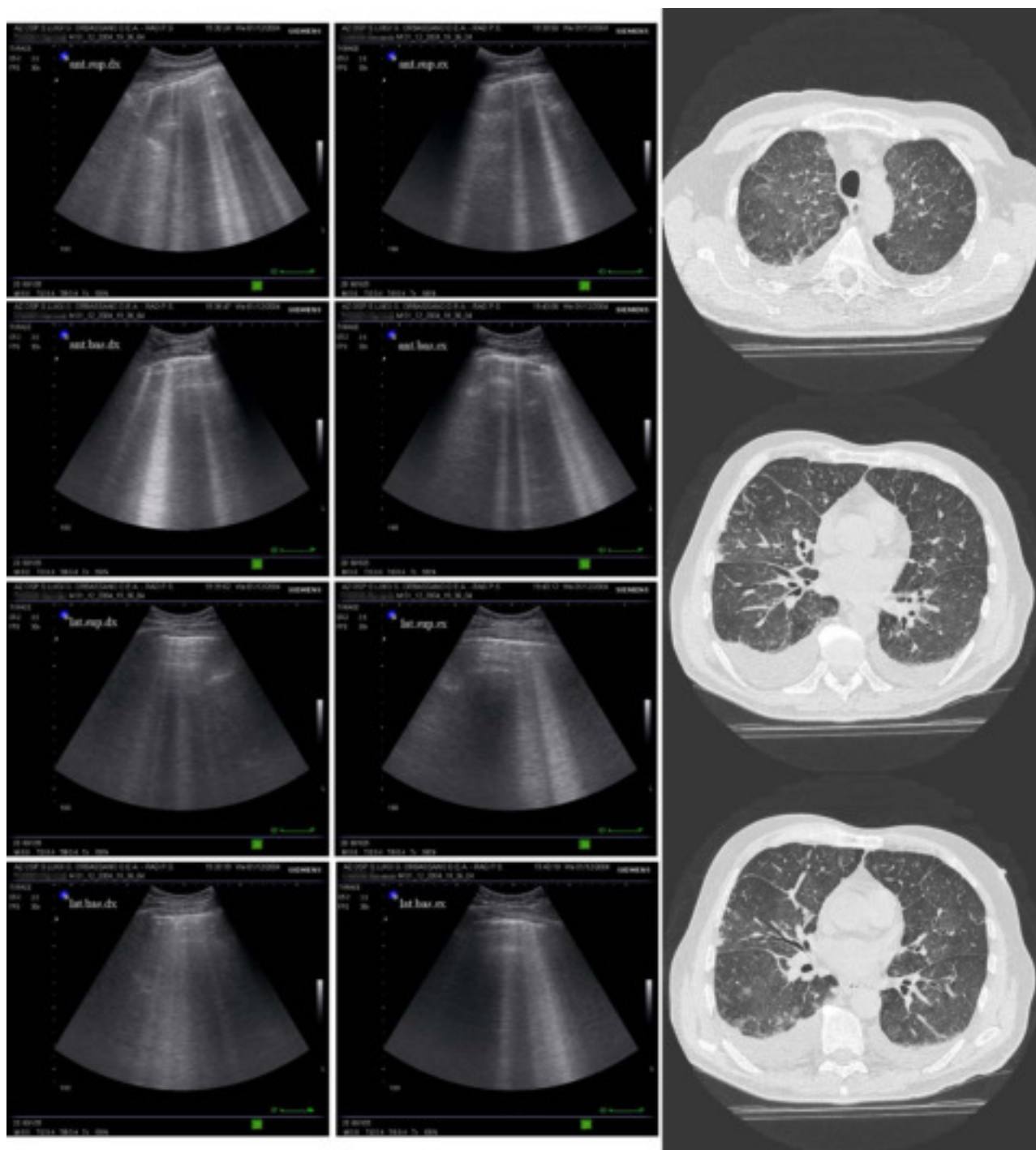
**3.3. Ultrasound versus computed tomography**

All the 18 CT scans corresponded to ultrasound. Five patients had AIS on CT, and all of them exhibited diffuse anterolateral artifacts. They were acute pulmonary edema (n = 3) and interstitial pneumonia (n = 2). In these cases, the CT showed diffuse thickened interlobular septa and/or diffuse and bilateral ground-glass areas all over the anterior and lateral surface of the lung (Figs. 4 and 5). The other 13 CT scans did not show diffuse AIS, and all these patients had negative ultrasound. Diagnosis of these were isolated pneumonia (n = 3), acute pericarditis (n = 1), lung cancer (n = 4), renal hematoma (n = 1), exacerbation of COPD (n = 2), and traumatic pleural effusion (n = 1).

**Table 2** Comparison between sonographic diagnoses of AIS and clinical outcomes

	Positive clinical diagnosis of AIS	Negative clinical diagnosis of AIS	Total
Positive sonographic AIS	64	7	71
Negative sonographic AIS	11	213	224
Total	75	220	295



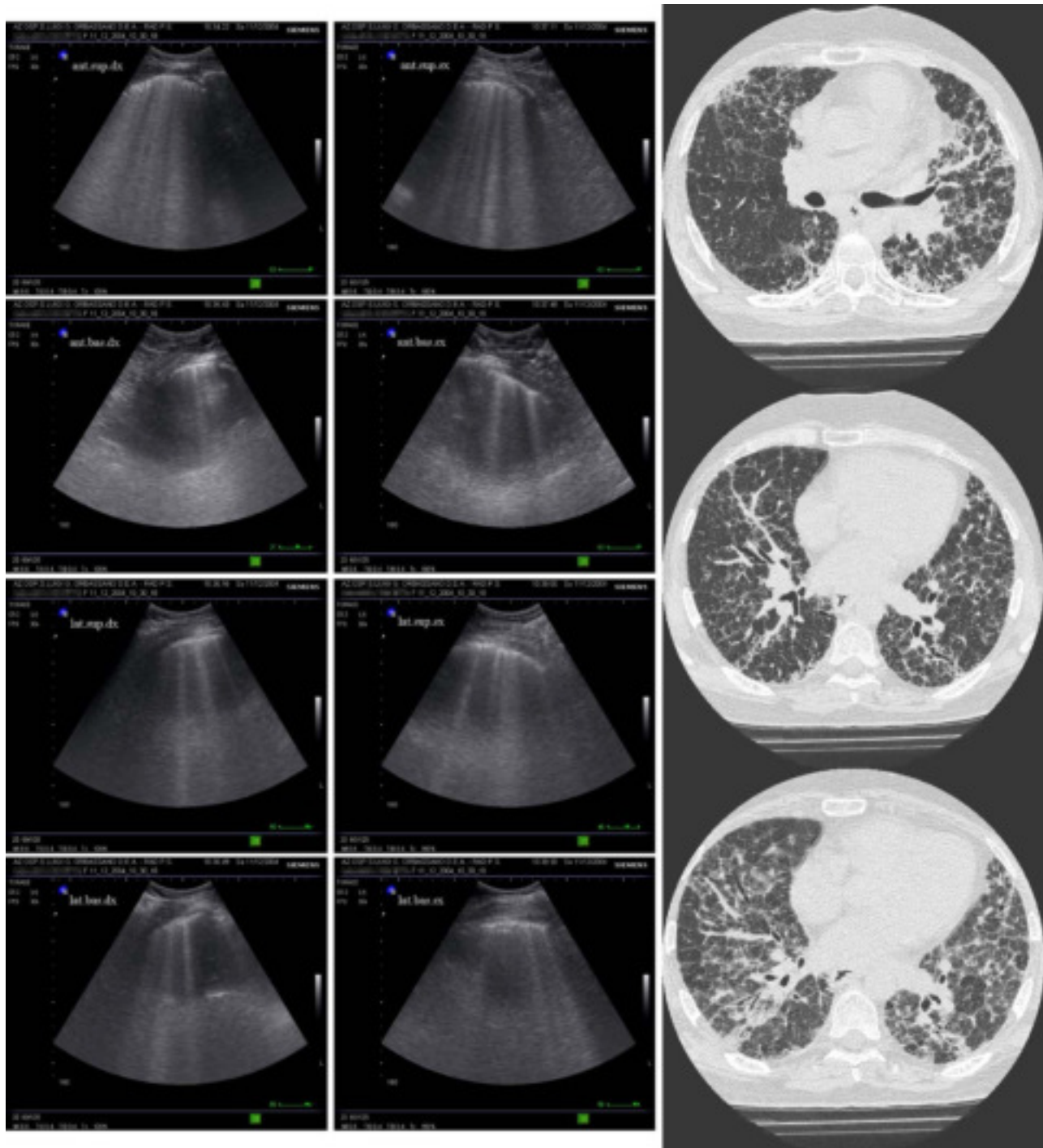


**Fig. 4** Diffuse interstitial pneumonia. (Left panel) Lung ultrasound pattern of diffuse AIS. (Right panel) Corresponding high-resolution CT showing multiple interstitial reticular thickening, some ground-glass areas, and bilateral pleural effusion.

In 17 cases, CT scan and ultrasound correlated also with the chest radiograph and clinical outcome. In one case, the CT did not agree with the chest x-ray. It was a case of idiopathic pulmonary hypertension without signs of respiratory failure at admission. In this case, the CT scan and ultrasound were normal, whereas at plain film, the radiologist described diffuse interstitial involvement.

#### 4. Discussion

Some authors previously showed that comet tail artifacts type B at lung sonography generate through resonance due to multiple reflection of the beam from thickened interlobular septa to lung surface [2-7,9]. In a series of critically ill patients admitted to an intensive



**Fig. 5** Idiopathic pulmonary fibrosis. (Left panel) Diffuse presence of B lines at lung ultrasound, together with thickened and irregular pleural line. (Right panel) Corresponding high-resolution CT showing bilateral thickened interlobular septa reaching the whole surface of the lung, with some right-sided and peripheral honeycomb patterns.

care unit, Lichtenstein et al [2] showed that the artifact and pulmonary subpleural thickened interlobular septa and/or ground-glass areas at CT were largely associated. The same authors observed that in healthy persons, the artifact can be limited to the last intercostal spaces, whereas it was diffused all over the lung surface in patients with pulmonary edema, pulmonary fibrosis, and

ARDS. They found an association between the presence of the artifact and radiologic AIS. Both sensitivity and specificity increased when the presence of an artifact limited laterally to the last intercostal space was considered as a feature of the normal lung. They concluded that the detection of the comet tail artifact is reasonably accurate to allow diagnosis of AIS, but they did not

**Table 3** Positivity (percent) at each of the 8 chest areas studied in 64 patients with clinical diagnosis of AIS and ultrasound lung pattern of diffuse B lines

	Right chest (%)	Left chest (%)
Anterior upper	67.2	65.6
Anterior lower	73.4	71.9
Lateral upper	78.1	85.9
Lateral basal	93.8	93.8

define exactly the feature of a pathologic lung ultrasound [2].

The first objective of our study was to determine the accuracy of the artifact in diagnosing AIS in patients admitted to an emergency medicine ward. Such patients are less severely ill and with a wider variety of diagnosis than patients admitted to an intensive care unit. Nevertheless, in our series, sensitivity and specificity of the artifact in diagnosing AIS using the x-ray picture as gold standard were satisfactory. Moreover, when comparing the ultrasound diagnosis with the clinical outcome, the accuracy of the test in diagnosing clinical AIS was similarly high. Interstitial lung involvement, either acute or chronic, mild or severe, led to the presence of the artifact in our series. Particularly, acute pulmonary edema, interstitial pneumonia, and chronic interstitial diseases mostly showed diffuse B lines at bedside lung ultrasound. Positivities at ultrasound for each of the 8 chest windows are shown on Table 3.

Eleven patients exhibited negative ultrasounds but positive radiographs. They were 8 cases of acute left heart failure, 2 cases of exacerbation of COPD, and 1 case of pneumonia. Ultrasound was performed within 48 hours, whereas chest radiograph was obtained always at presentation in the ED. This delay may explain the discordant findings of the 2 tests in the 8 cases of congestive heart failure, as a result of resolution of interstitial lung involvement due to treatment. Although in all these 8 cases artifacts were present in at least 3 scans, criteria for diagnosing diffuse sonographic AIS were not met. In the other 3 discordant cases, the absence of diffuse artifacts at ultrasound was consistent with the clinical outcome because exacerbation of COPD and isolated pneumonia are not included in AIS. It must be said that the radiologic detection of interstitial syndrome is often questionable and subjective, particularly when the radiologist read chest films of bad quality.

Five patients exhibited a positive ultrasound with a negative chest x-ray. One of them had a final diagnosis positive for AIS (congestive heart failure during acute bronchitis). The other 4 had a clinical outcome negative for AIS. They were 2 cases of unilateral pneumonia, 1 patient with fever of unknown origin and 1 patient with rheumatoid arthritis. In the latter case, we could hypothesize that the artifact is detectable at a very early stage of pulmonary interstitial involvement in a collagen vascular disease, and

this could be a matter of a future study trial. We cannot explain the other 3 cases with positive ultrasound but negative plain film and clinical outcome. In all 3 cases, the ultrasound showed 2 positive scans per side.

Another objective of our study was to define the criteria needed to diagnose diffuse alveolar syndrome at lung ultrasound in noncritically ill patients. Lichtenstein et al defined adequately the features of a normal ultrasound, that is, B lines either absent or limited to the last intercostal space above the diaphragm. They also defined an abnormal sonographic scan, with at least 3 B lines. A general definition of a lung ultrasound diagnostic of AIS is still lacking. According to our experience, diagnosing diffuse AIS requires at least 2 positive scans per side. Our series of cases was analyzed according to such a criterion. We observed 63 patients with isolated alveolar consolidation (pneumonia, cancer, or other) without diffuse AIS, and most of them exhibited comet tail artifacts just in the area surrounding the lung consolidation. In 60 of these, the lung ultrasound did not meet our criteria for diagnosing diffuse AIS (see Table 1). On the contrary, all 9 cases of interstitial pneumonia or multiple and bilateral pneumonia studied exhibited positive ultrasound patterns.

The skill to recognize a pathologic pattern at lung ultrasound was easily acquired by radiologists and emergency physicians. Feasibility and reproducibility of the exam were good, and all the physicians involved judged it as an easy-to-use diagnostic tool. As for the clinical significance of sonographic AIS, the bedside diagnosis of AIS in dyspneic patients is useful particularly in the emergency setting [10]. Chest radiograph is not always decisive [11,12]. The rapid recognition of B lines allows to distinguish between different sources of respiratory failure. According to the literature, sonographic comet tail artifacts may be useful for ruling out pneumothorax [13] and differentiating cardiogenic pulmonary edema from decompensated COPD [14]. This is particularly valuable when a high-quality chest radiograph cannot be quickly obtained, and diagnosis is not clinically straightforward. Moreover, many EDs lack a radiologist at night and during weekends, whereas the interpretation of a bedside-performed chest x-ray, often of bad quality, is not always easy for the attending emergency physician.

#### 4.1. Limitations

Whereas our study shows the advantages of ultrasound detection of AIS compared to chest radiograph, it must be acknowledged that the latter is not the best gold standard for the study of lung interstitium. The accuracy of ultrasound in detecting AIS should be assessed in comparison with high-resolution CT. However, in the everyday practice in EDs, clinical decisions must be taken in the absence of findings obtained with the latter technique. The purpose of the present study was to compare ultrasound with the test ordinarily used to evaluate lung interstitium in the emergency setting.

## 4.2. Conclusion

In the present study, we showed the usefulness of lung ultrasound in the detection of AIS. Specific comet tail B line is a lung ultrasound sign reasonably accurate for diagnosing diffuse radiologic alveolar-interstitial involvement at bedside and to suggest AIS as clinical outcome. This test is a simple, feasible, and easy-to-use bedside diagnostic tool for the emergency physician. Implementation of clinical examination and routine investigations with lung ultrasound should lead to more accurate initial diagnoses of dyspneic patients in the ED.

## Acknowledgment

The authors are grateful to Prof. Benedetto Terracini for his important help in translation of this work.

## References

- [1] Ziskin MC, Thickman DI, Goldenberg NJ, et al. The comet tail artifact. *J Ultrasound Med* 1982;1:1-7.
- [2] Lichtenstein D, Mézière G, Biderman P, et al. The comet tail artifact. An ultrasound sign of alveolar-interstitial syndrome. *Am J Respir Crit Care Med* 1997;156:1640-6.
- [3] Lichtenstein D. Pneumothorax and introduction to ultrasound signs in the lung. In: Heilmann U, Wilbertz H, Gosling A, editors. *General ultrasound in the critically ill*. 1st ed. Heidelberg: Springer-Verlag; 2005. p. 105-15.
- [4] Reissig A, Kroegel C. Transthoracic sonography of diffuse parenchymal lung disease. The comet tail artifacts. *J Ultrasound Med* 2003;22:173-80.
- [5] Targhetta R, Chavagneux R, Balmes P, et al. Sonographic lung surface evaluation in pulmonary sarcoidosis: preliminary results. *J Ultrasound Med* 1994;13:381-8.
- [6] Jambrik Z, Monti S, Coppola V, et al. Usefulness of ultrasound lung comets as a nonradiologic sign of extravascular lung water. *Am J Cardiol* 2004;93:1265-70.
- [7] Agricola E, Bove T, Oppizzi M, et al. "Ultrasound comet-tail images": a marker of pulmonary edema: a comparative study with wedge pressure and extravascular lung water. *Chest* 2005;127:1690-5.
- [8] Wang CS, FitzGerald JM, Schulzer M, et al. Does this dyspneic patient in the emergency department have congestive heart failure? *JAMA* 2005;294:1944-56.
- [9] Lichtenstein D. Lung. In: Heilmann U, Wilbertz H, Gosling A, editors. *General ultrasound in the critically ill*. 1st ed. Heidelberg: Springer-Verlag; 2005. p. 116-28.
- [10] Chakko S, Woska D, Martinez H, et al. Clinical, radiographic, and hemodynamic correlations in chronic congestive heart failure: conflicting results may lead to inappropriate care. *Am J Med* 1991; 90:353-959.
- [11] Siefkin AD. Dyspnea in the elderly: cardiac or pulmonary? *Geriatrics* 1984;39:46-52.
- [12] Wasserman K. Dyspnea on exertion: is the heart or the lungs? *JAMA* 1982;248:2039-43.
- [13] Lichtenstein D, Mézière G, Biderman P, et al. The comet-tail artifact: an ultrasound sign ruling out pneumothorax. *Intensive Care Med* 1999;25:383-8.
- [14] Lichtenstein D, Mézière G. A lung ultrasound sign allowing bedside distinction between pulmonary edema and COPD: the comet tail artifact. *Intensive Care Med* 1998;24:1331-4.