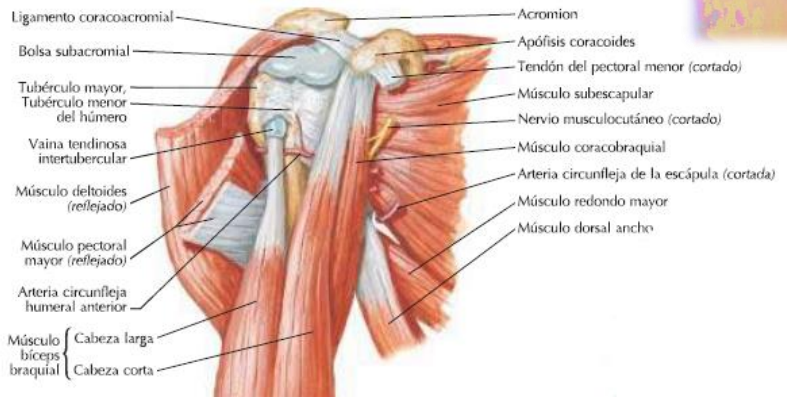
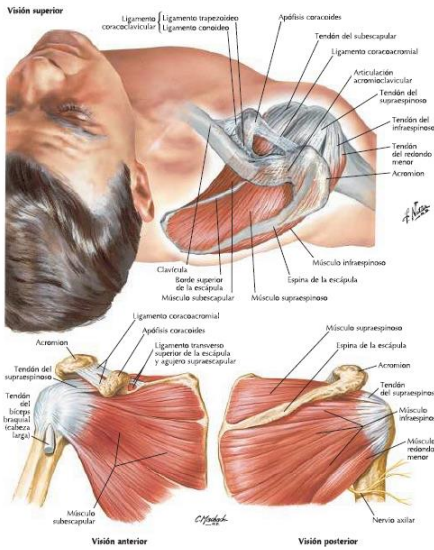


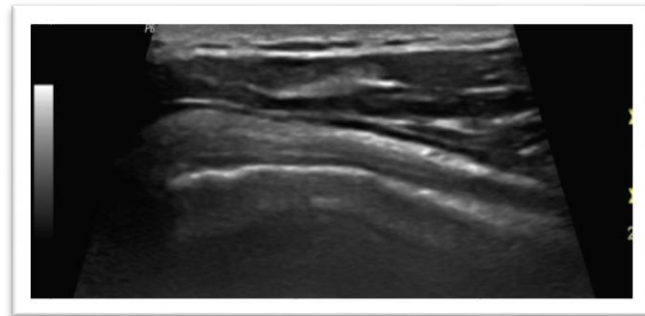
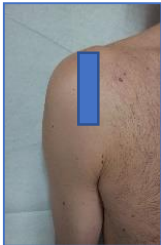
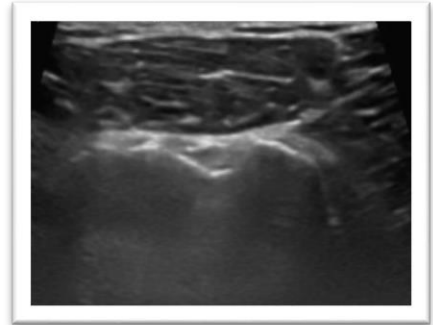
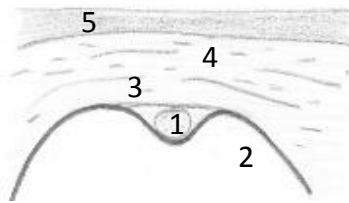
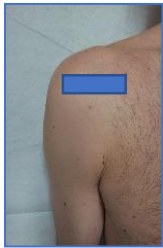Taller de ecografía del hombro

V JNE 2018 Madrid

Recuerdo Anatómico

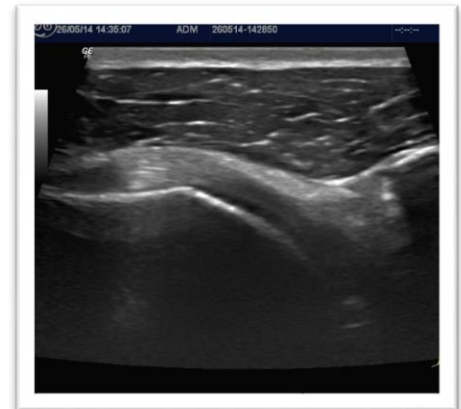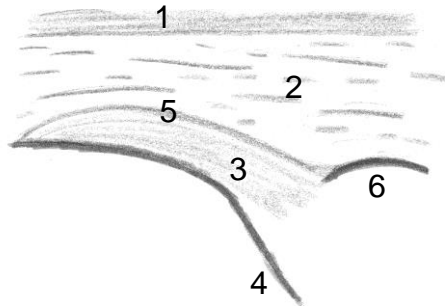

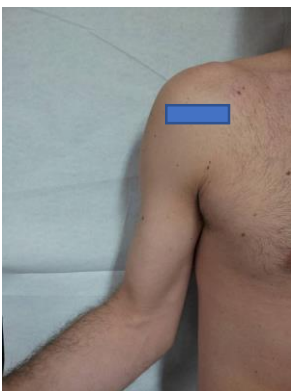
Tendón del Biceps



- 1 Tendón del biceps
- 2 Cortical del húmero
- 3 Ligamento transversario
- 4 Músculo deltoides
- 5 Tejido Celular subcutáneo

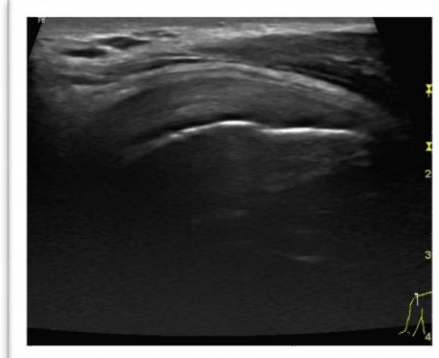
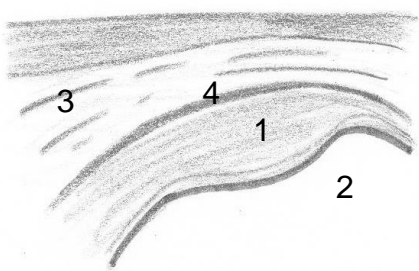
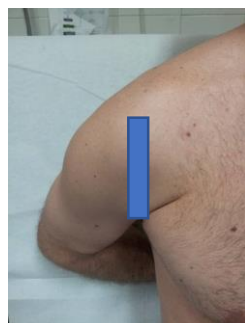
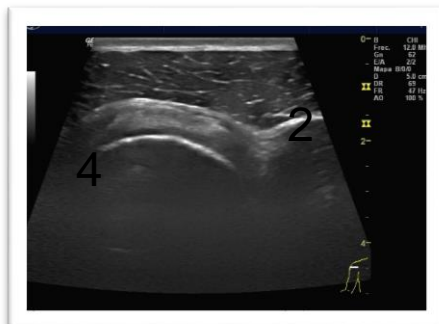
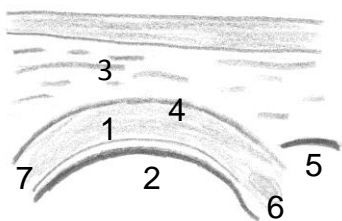
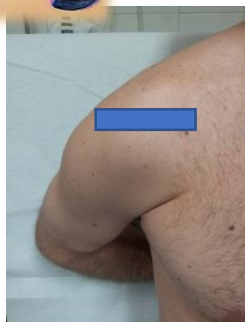Tendón del Subescapular



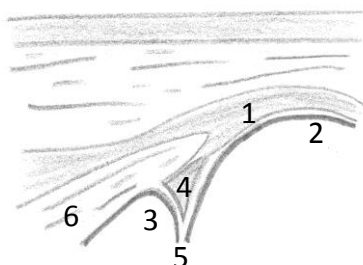
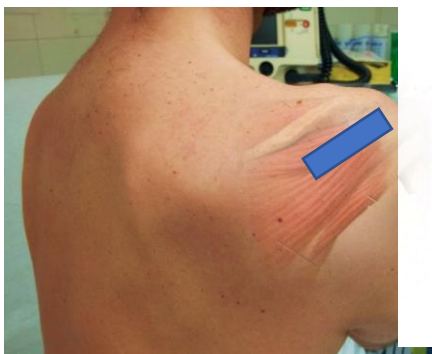- 1 Tejido celular subcutáneo
- 2 Deltoides
- 3 Tendón del subescapular
- 4 Cortical humeral
- 5 Bursa subcoracoidea
- 6 Apófisis coracoides

Tendón del Supraespinoso

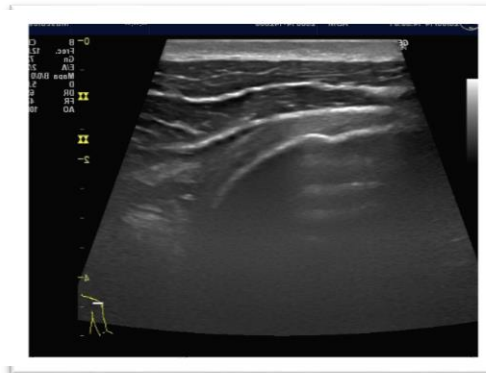
- 1 Tendón del supraespinoso.
- 2 Cortical humeral
- 3 Deltoides
- 4 Bursa subacromial subdeltoidea
- 5 Apófisis coracoides
- 6 Corredera bicipital
- 7 Tendón del infraespinoso



Tendón del Infraespinoso y redondo menor



- 1 Tendón del infraespinoso
- 2 Cabeza humeral
- 3 Cavidad glenoidea
- 4 Rodete glenoideo
- 5 Articulación glenohumeral
- 6 Músculo infraespinoso



Articulación acromioclavicular

